

*Rapid Prototyping, surgery planning, fractures*

*Przemysław KRAKOWSKI* [0000-0001-7137-7145]\*

*Józef JONAK* [0000-0003-4658-4569]\*\*

*Robert KARPINIŃSKI* [0000-0003-4063-8503]\*\*

*Łukasz JAWORSKI* [0000-0002-4384-5754]\*\*\*

## USEFULNESS OF RAPID PROTOTYPING IN PLANNING COMPLEX TRAUMA SURGERIES

### Abstract

*Orthopaedic trauma surgery is a complex surgical speciality in which anatomy, physiology and physics are mixed. Proper diagnosing and based on that planning and performing surgery is of crucial matter. This article presents usefulness of 3D reconstruction in diagnostics and surgical planning. It focuses on utility of computed tomography reconstruction in trauma surgery. Moreover, two cases in which this technique was used is described. Complex 3D reconstruction proved its usefulness and in future it may become a modality of choice for planning complex trauma procedures in which standard implants and approaches are insufficient.*

### 1. INTRODUCTION

Trauma to the lower extremity can be a devastating incident for every individual. Among various injuries affecting lower extremity, tibial fractures are one of the most common. The incidence of all tibia fractures is estimated 13 in 100000 persons per year (Decruz, Antony Rex & Khan, 2019). These fractures can be divided into

---

\* Orthopaedic Department, Łęczna Hospital, Krasnystawska 52, 21-010 Łęczna, Poland

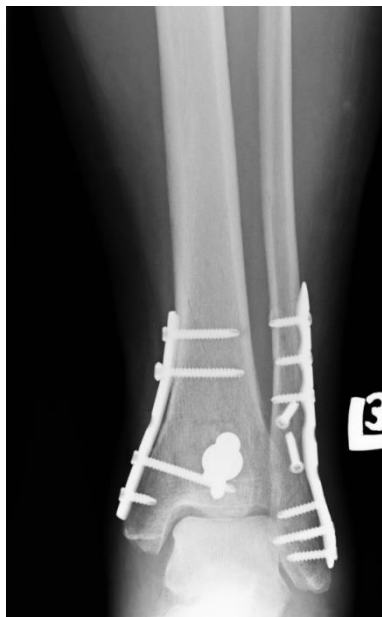\*\* Lublin University of Technology, Faculty of Mechanical Engineering, Department of Machine Design and Mechatronics, Nadbystrzycka 36, 20-618, Lublin, Poland, j.jonak@pollub.pl, r.karpinski@pollub.pl

\*\*\* Independent researcher, Lublin, Poland

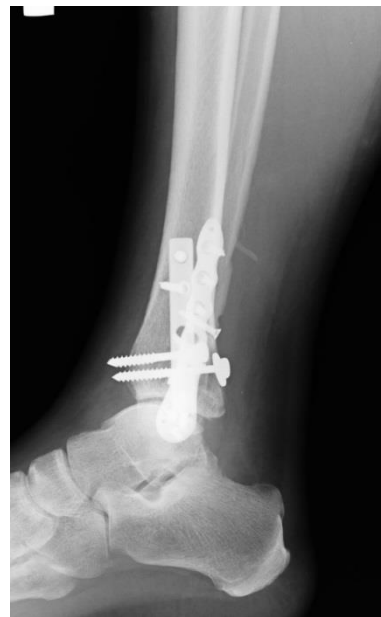proximal, shaft and distal tibia fractures differing in optimal treatment method, surgical approach and anticipated treatment result. Every fracture treatment can be perceived as a mix of anatomy, physiology and physics. Fractures affecting joints such as knee or ankle if treated improperly lead to malunion, joint range of motion loss and persistent pain. Even though fractures affecting proximal and distal end of tibia are less common than affecting diaphyseal region (Court-Brown & Caesar, 2006), the impact of these fractures on daily living is much greater if treated incorrectly. Therefore, planning of surgical treatment is of vital importance in order to create best possible outcome for the patient. Complex joint fractures require meticulous planning. Up to this date the gold standard in fracture diagnosis is conventional X ray Introduced in 1895 by Wilhelm Conrad Röntgen (On a New Kind of Rays, 1896). Before that, orthopaedic diagnostic was limited to simple observation of limb alignment or pathological movement on fracture site. The invention was introduced to everyday practice. Up to this day, plain X-rays are the work horse for trauma surgeons (American College of Surgeons, 2012; Bégué, 2014). It is cheap, widely used and available in almost any trauma setting. The sensitivity of radiography In orthopaedic diagnostics usually 2 views are required in 90 degree rotation of the films. However, in some cases such as scaphoid fractures, around 25% of fractures can be overlooked on initial X-rays (Jenkins, Slade, Huntley & Robinson, 2008). Similarly in paediatric orthopaedics, fractures often are occult and not visible on first presentation on plain X-rays due to unique characteristics of the paediatric skeleton which can cause troubles with diagnosing the fracture (Segal & Shrader, 2013). In 1961 Oldendorf (1961) published his work which was a mile stone for creating commercially available computed tomography (CT) scanners which was introduced in 1972 (Richmond, 2004). Computed tomography can bring a great insight into the fracture lines, however plain CT in transversal cuts can be misleading in clinical setting. Therefore, complex 3D reconstruction of the fractures is necessary for proper planning. CT is routinely used in articular fractures, where up to 31% of articular surface depression cannot be visible on plain radiograph (Dale, Ha & Chew, 2013). Apart from obvious misdiagnosed fractures In this article we are presenting a case studies of two patients treated in Orthopaedic Department of Leczna Hospital with complex articular fractures, where surgical planning was performed on high resolution 3D reconstructions in order to facilitate the surgery.

## 2. CASE PRESENTATIONS

A 50 year old female suffered a complex fracture of distal tibia and fibula after being hit by a car. At the time of admission through physical examination was performed. The physical evaluation revealed distal tibia deformation, tenderness and swelling. The initial X-rays showed complex, articular distal tibia fracture. Until planned surgery the patient was immobilised in a cast. The CT scans were obtained and 3D reconstructions were rendered. The planning of surgery was performed on 3D reconstructions of the fracture sites. The 3D reconstructions enabled detailed surgical planning. And significantly aided during procedure, while all necessary implants were prepared in advance with the knowledge of exact screw length which were to be used. During the surgery itself, knowledge of implants length was a great help during the procedure while it was a simple and fast method of confirmation of implant placement. And if there was a mismatch between planned and measured implant the surgeon had a feedback that probably the placement or angle of the implant is false. This enabled the operating surgeon for anatomical reduction of the fracture and adequate placement of implants. Postsurgery X-rays show excellent reduction and fixation on Figures 1–2.

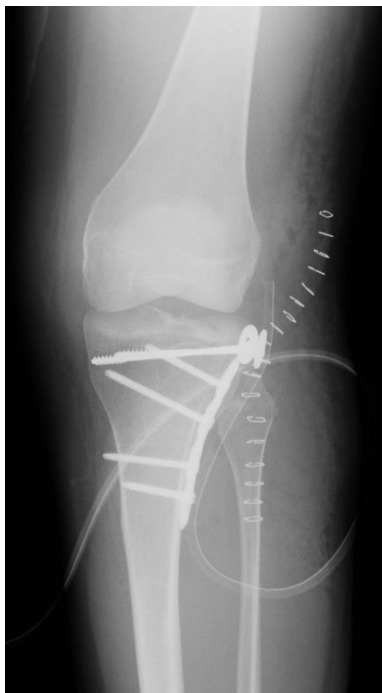

**Fig. 1. AP postoperative X-ray**

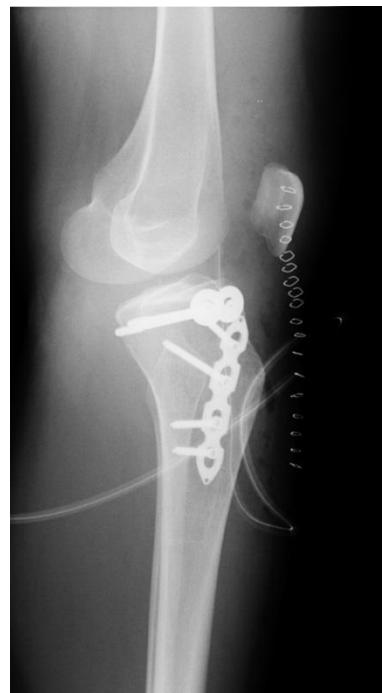

**Fig. 2. Lateral postoperative X-ray**

A 30 year old female was admitted to the hospital due to lateral tibial condyle fracture sustained during a standing height fall. The patient had a prior history of juvenile osteoporosis and multiple bone deformations were encountered including proximal tibia deformation. Moreover the length of the bones was shortened which is typical for metabolic bone diseases (Skowrońska-Jóźwiak & Lorenc, 2006). The fracture was diagnosed as Schatzker type I fracture. In normal setting this type of fracture is rather straightforward in treatment, however in this case due to bony ends deformations and abnormal limb length 3D reconstruction was a great assistance in surgical planning. It was seen that typical proximal tibial implants would not fit to the deformed bone, therefore on basis of 3D reconstruction a trial implants were introduced in order to select the best fitting implants. Based on 3D reconstructions a straight plate, which was bended to fit the bone was introduced. Additional fixation was achieved by inserting additional screws apart from plate. Proper implant placement regardless of congenital deformity of proximal tibia is shown on Figures 3–4.



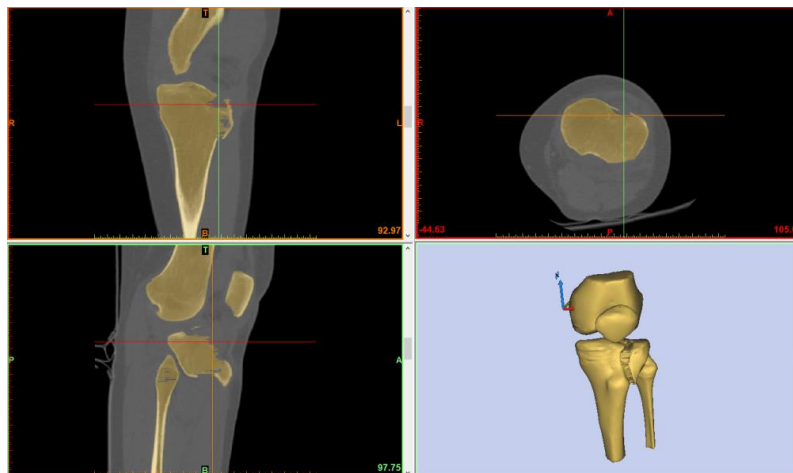
**Fig. 3. AP postoperative X-ray**



**Fig. 4. Lateral postoperative X-ray**

### 3. DEVELOPING OF THE VIRTUAL MODELS

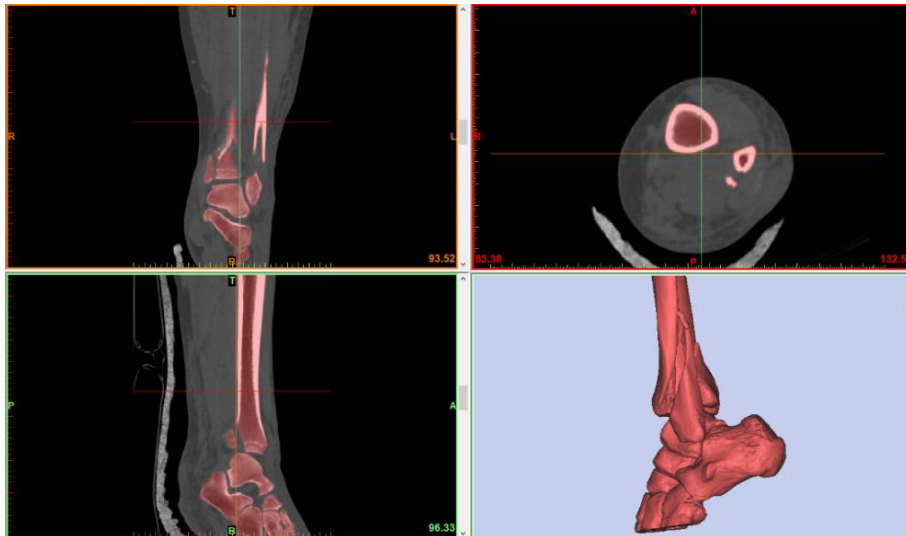
3D models of the analyzed cases were based on a series of 2D images perpendicular to the axis of long bones obtained by computed tomography. The images were exported to a file in the DICOM (Digital Imaging and Communications in Medicine) format. This format allows the exchange and interpretation of medical data related to diagnostic images in medicine. It is mainly used in the processing of computed tomography (CT) images, magnetic resonance imaging (RM). Data in the DICOM format usually has a large volume, but it allows you to maintain high image quality. In the next step, the image series were implemented in Materialise Mimics 17.0, where, based on the source files, the program calculates cross-sections in two parallel planes arranged perpendicular to the long axis of the bone. Then, using the conversion function from two-dimensional data in the form of pixels to three-dimensional pixels called voxels. Creating a virtual model using the thresholding function is based on thresholding radiological density values expressed in the Hounsfield Scale.



**Fig. 5. Calculation of 3D model for proximal tibia fracture**

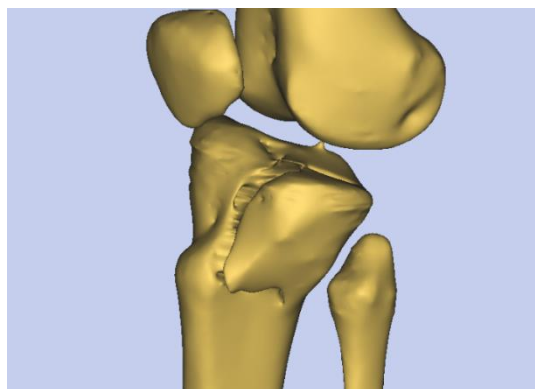
The range of this scale is from  $-1000$  HU for air, to about  $3100$  HU for bone tissue. It is represented by 12-bit images, where the areas closer to white correspond to structures that absorb more radiation, while the areas closer to black correspond to structures that absorb less radiation. Specific ranges of variation HU units correspond to the anatomical structures. The radiological density range for bone tissue is from  $+300$  to  $+400$  HU for spongy bone and from  $+1800$  to  $+1900$  HU for cortical bone. In the case of the analyzed set of images, structures with radiological density from  $226$  to  $1852$  HU were isolated. When the tissue mask

with the desired radiological density is ready, it begins to calculate the 3D model based on highlighted tissues on layers in three perpendicular planes of the 3D coordinate system. This process for both analyzed cases is presented in Fig. 5 and Fig. 6.

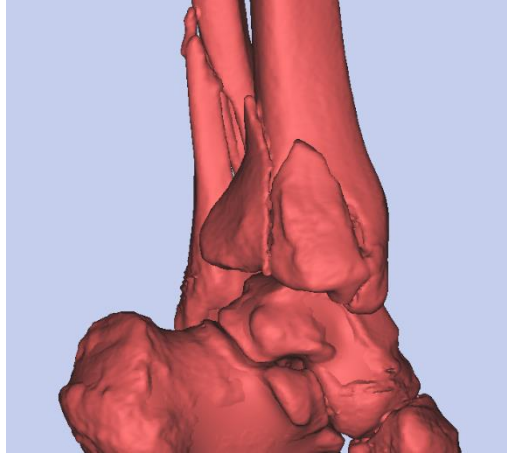


**Fig. 6. Calculation of 3D model for distal tibia fracture**

For better model quality, voids inside the bone were filled using the “Fill cavities from polylines” tool, which fills the empty strokes (polylines) created on the basis of cross-section sketches of the initial 3D model on each layer of the image. The results are shown in Figures 7 and 8.



**Fig. 7. Final 3D model of proximal tibia fracture**



**Fig. 8. Final 3D model of distal tibia fracture**

The models obtained in this way provide the operator with much more information about fracture, especially in terms of the size and distribution of bone fragments. It is also possible to estimate the volume of cavities, which allows you to prepare the right amount of material to fill them. The use of Rapid Prototyping technology in the broadly understood planning of orthopedic procedures allows for the appropriate selection of surgical instruments, which can reduce the time of the procedure and reduce its costs in comparison with procedures performed without using this technology. Moreover, thanks to additive manufacturing processes in form of 3D printing, physicians are able to practise each procedure on life-size models, derived from digital models (e.g. in STL file format) and 3D printed using affordable plastic materials.

#### **4. CONCLUSIONS**

Trauma surgery requires complex and often multidisciplinary approach. Radiological assessment of the fracture sites and adjacent soft tissues is crucial for proper surgery planning. Several imaging modalities may be incorporated in diagnostic and planning protocol including conventional radiography, CT or MRI. Nevertheless, each trauma case can differ significantly from previous cases and may require individual approach. In simple fractures, the surgery is rather straightforward. However, intraarticular fractures, especially in deformed limbs can be a challenging and restoring individual anatomy may not be possible without high resolution 3D reconstructions with trial implant templates placement can be a great help in surgical planning. It gives insight into the fracture which cannot be obtained otherwise.

## REFERENCES

- American College of Surgeons. (2012). *Advanced trauma life support: ATLS; student course manual* (9. ed). Chicago, Ill: American College of Surgeons.
- Bégué, T. (2014). Articular fractures of the distal humerus. *Orthopaedics & Traumatology: Surgery & Research*, 100(1), S55–S63. doi:10.1016/j.otsr.2013.11.002
- Court-Brown, C. M., & Caesar, B. (2006). Epidemiology of adult fractures: A review. *Injury*, 37(8), 691–697. doi:10.1016/j.injury.2006.04.130
- Dale, J. D., Ha, A. S., & Chew, F. S. (2013). Update on Talar Fracture Patterns: A Large Level I Trauma Center Study. *American Journal of Roentgenology*, 201(5), 1087–1092. doi:10.2214/AJR.12.9918
- Decruz, J., Antony Rex, R. P., & Khan, S. A. (2019). Epidemiology of inpatient tibia fractures in Singapore – A single centre experience. *Chinese Journal of Traumatology*, 22(2), 99–102. doi:10.1016/j.cjte.2019.01.004
- Jenkins, P. J., Slade, K., Huntley, J. S., & Robinson, C. M. (2008). A comparative analysis of the accuracy, diagnostic uncertainty and cost of imaging modalities in suspected scaphoid fractures. *Injury*, 39(7), 768–774. doi:10.1016/j.injury.2008.01.003
- Oldendorf, W. H. (1961). Isolated flying spot detection of radiodensity discontinuities – Displaying the internal structural pattern of a complex object. *IRE Transactions on Bio-Medical Electronics*, BME-8, 68–72.
- On a New Kind of Rays. (1896). *Nature*, 53(1369), 274–276. doi:10.1038/053274b0
- Richmond, C. (2004). Sir Godfrey Hounsfield. *BMJ*, 329(7467), 687.1. doi:10.1136/bmj.329.7467.687
- Segal, L. S., & Shrader, M. W. (2013). Missed fractures in paediatric trauma patients. *Acta Orthopaedica Belgica*, 79(6), 608–615.
- Skowrońska-Józwiak, E., & Lorenc, R. S. (2006). Metabolic bone disease in children: Etiology and treatment options. *Treatments in Endocrinology*, 5(5), 297–318.