

medical imaging, 3D reconstructions, orthopaedic trauma surgery

Przemysław KRAKOWSKI*, Robert KARPIŃSKI**,
Marcin MACIEJEWSKI***

APPLICATIONS OF MODERN IMAGING TECHNOLOGY IN ORTHOPAEDIC TRAUMA SURGERY

Abstract

Orthopaedic trauma surgery is a complex surgical speciality in which anatomy, physiology and physics are mixed. Proper diagnosing and based on that planning and performing surgery is of crucial matter. This article briefly summarizes available radiological modalities used for diagnostics and for surgical planning. It focuses on utility of rapid prototyping process in trauma surgery. Moreover, a case study in which this technique was used is described. Rapid prototyping proved its usefulness and in future it may become a modality of choice for planning complex trauma procedures.

1. INTRODUCTION

Orthopaedic surgery can be easily called a mix of anatomy, physiology and physics. Every day orthopaedic surgeons deal with complex fractures, limb malalignments or developmental disorders that influence axis of the limbs. Bones are connected with soft tissues which put strain on the structure of the bone and in case of fractures, they generate fracture distraction and malalignment. The same forces act on musculoskeletal system in developmental diseases or posttraumatic axis alterations. Therefore, in planning complex surgical procedures, surgeons have to

* Orthopedic Department, Łęczna Hospital, Krasnystawska 52, 21-010 Łęczna, Poland

** Department of Machine Design and Mechatronics, Faculty of Mechanical Engineering, Lublin University of Technology, Nadbystrzycka 36, 20-618 Lublin, Poland, r.karpinski@pollub.pl

*** Institute of Electronics and Information Technology, Faculty of Electrical Engineering and Computer Science, Lublin University of Technology, Nadbystrzycka 36, 20-618 Lublin, Poland

take under consideration various forces, which will affect the bones. The complex 3D structure of bones is often hard to reconstruct. Meticulous surgical planning is of great importance to successful performing a complex surgery. Therefore, orthopaedic and engineering society seek methods that could enhance planning of complex surgical procedures. A wide variety of imaging solutions is available for usage of orthopaedic surgeons including plain X-rays, ultrasound, (US), computed tomography (CT) or magnetic resonance imaging (MRI). Every of these modalities has its unique features, advantages and disadvantages. However, even having such a wide variety of imaging solutions, orthopaedic surgeons often come to a point where these modalities are not capable of providing adequate data concerning complex fractures or limbs deformities. Even having a 3D reconstruction of bone, which is to be operated, in some instances is not sufficient to fully understand the complexity of the bone geometry. A solution to that problem might be 3D printing based on CT scans of the affected limb (Mulford, Babazadeh & Mackay, 2016). This article was written to show possible future paths to improving medical imaging techniques.

2. IMAGING TECHNIQUES

The inventor of X-rays was Wilhelm Röntgen, who published his first paper in 1896 (Röntgen, 1896). Before that, orthopaedic diagnostic was limited to simple observation of limb alignment or pathological movement on fracture site. The invention was introduced to everyday practice. Up to this day, plain X-rays are the work horse for trauma surgeons (The ATLS Subcommittee et al., 2012; Bégué, 2014). It is cheap, widely used and available in almost any trauma setting. In orthopaedic diagnostics usually 2 views are required in 90 degree rotation of the films. However, in some cases such as scaphoid fractures, around 25% of fractures can be overlooked on initial X-rays (Jenkins, Slade, Huntley & Robinson, 2008). Similarly in paediatric orthopaedics, fractures often are occult and not visible on first presentation on plain X-rays due to unique characteristics of the paediatric skeleton which can cause troubles with diagnosing the fracture (Segal & Shrader, 2013). Moreover, conventional radiographs show only flat image of 3D bone structure. Nevertheless, conventional radiography is the first method of choice in diagnosing traumatic lesions, due to its simplicity, cost-effectiveness and accessibility. As mentioned above, bones are a 3D structures, with multiple soft tissue attachments to its surface, which influence the bone behaviour during trauma or other diseases. Therefore planning a complex procedure on simple X-rays is often hard and inadequate in details, which can impair surgical outcome. Therefore introduction of CT was of great importance for orthopaedic surgery.

CT is a routinely used imaging method since 1972 when the first commercial CT scanner was introduced (Richmond, 2004). Since that time the use of CT increased intensively (Berrington de González et al., 2009). It uses X-ray beams which are passed through a body and produce a set of data which can be manipulated in order to demonstrate various organs based on their ability to capture X-ray beam. Modern CT scanners and its software are capable of creating images in transverse, sagittal and coronal planes. Moreover, the data collected during scanning can create a 3D image of the affected bone with some adjacent soft tissues such as peroneal tendons in calcaneal fractures (Ohashi et al., 2015). The sensitivity for diagnosing peroneal dislocation was similar to the findings based on MRI evaluation. CT has also the advantage of diagnosing even small osteochondral fractures, which are usually occult in plain X-rays. CT is therefore, routinely used in intra-articular fractures, where up to 31% of depression fractures are missed by conventional radiography (Dale, Ha & Chew, 2013). Moreover, with technical advancement creating a intraoperative CT scanners was possible, which can be used in intraoperative control of reposition and fixation of complex fractures like foot or pelvis (Cunningham, Jackson & Ortega, 2014; Kemppainen, Pennock, Roodcroft, Bastrom & Mubarak, 2014).

Magnetic resonance was introduced in 1973 (Lauterbur, 1973) by Paul C. Lauterbur. Its medical use was slowly increasing since early eighties. Images are acquired due to high concentration of water in tissues. When introduced into a magnetic field hydrogen atoms emit radio frequency signal which is measured by receiving coil, and then the data is processed in order to create an image. Since MRI is capable of imaging soft tissues which contain water, it has wide range of use in orthopaedic surgery. The most common use of MRI is in diagnosing soft tissue and cartilage lesions in joints (Puig, Kuruvilla, Ebner & Endel, 2015; Rosas, 2014; Shindle et al., 2006). Magnetic resonance imaging has the highest sensitivity in detecting cartilage and soft tissue lesions reaching 91% for structures like meniscus (Crawford, Walley, Bridgman & Maffulli, 2007) and 94% for cartilage lesions (Wong, Han, Wong & Lee, 2017). MRI has also high sensitivity in detecting other lesions and diseases of musculoskeletal system. MRI is one the most sensitive imaging modalities in detecting bone marrow oedema which is main symptom of stress fractures, tumors or trauma (Shin, Morin, Germany, Jones & Lapinsky, 1996; Silva Jr. et al., 2013). Nevertheless, all these modalities has their own limitations, and frequently are not reliable in planning of the surgeries.

3. COMPUTED NAVIGATION

Orthopaedic surgery is one of the most demanding specialities when performing complex procedures. Due to 3D construction of bones, one must be prepared to re-create the length, axis and rotation of the bone that is to be treated. In case of fractures soft tissues bone attachments create forces that displace

fracture fragments. In total hip (THR) and total knee (TKR) replacements recreating of proper axis to facilitate painless and smooth movement of the joint is of vital importance. Also tumorous resections require sophisticated planning in order to reconstruct the bone and overlying tissues. For this reason, computer-assisted orthopaedic surgery (CAOS) was introduced. Since the end of XX century more and more applications of CAOS were proposed. Before the advent of computed tomography the main source of information for orthopaedic surgeons were plain 2D X-rays, which were susceptible to errors resulting from magnification of X-ray or malpositioning of the patient during radiography. CT is free from these potential errors. Therefore, it can be used for proper planning of the surgery. Different methods of assisting the surgery were implemented including robots (Taylor et al., 1999) which perform crucial steps of the procedure. Also during total knee or total hip replacements, surgeons can use patient-specific guides. The guides are prepared on basis of MRI or CT of individual patient. It was shown that using patient-specific guides facilitate better limb alignment in complex joint replacement cases (MacDessi, Jang, Harris, Wheatley, Bryant, & Chen, 2014). Even though computer-assisted navigation has its benefits, it is hard to implement in everyday practice in operating room. The main obstacles in implementing CAOS in OR are: operating room setup, maintaining the correct alignment, or surgery time (Rahmathulla, Nottmeier, Pirris, Deen & Pichelmann, 2014). Guiding systems were found to have lower complication rate in spinal surgery (Rahmathulla et al., 2014). It was also shown that main weaknesses of the CAOS based on surgeons opinions were: intra-operative glitches, unreliable accuracy, frustration with intra-operative registration and line-of-sight issues (Zheng & Nolte, 2015).

The basic elements of every CAOS system are: the virtual object which is defined as representation of structures which allow surgeon to plan procedure. Virtual objects can be acquired prior to surgery or intraoperatively. In the beginning of CAOS all data was collected prior to surgery, however this approach had its limitations such as changes in bony anatomy between planning and performing surgery. Therefore, usage of intraoperative CT has been proposed (Jacob, Messmer, Kaim, Suhm, Regazzoni & Baumann, 2000). However, intra-operative usage of CT exposes medical professionals and patient to great level of radiation. Moreover, creating a space for intra-operative CT in the setting of operating room requires large investments in the infrastructure. Due to limitations of CT intra-operative usage new modalities were introduced including 3D fluoroscopic image data which proved to provide adequate information (Rajasekaran, Karthik, Ravi Chandra, Rajkumar & Dheenadhayalan, 2010). The next important part of CAOS is registration method which enables displaying the current location of the tool based on data collected previously. The techniques implemented in registration are surface matching (Bargar, Bauer & Börner, 1998; Bächler, Bunke & Nolte, 2001), 2D and 3D fluoroscopic images (Zheng, Kowal, González Ballester, Caversaccio & Nolte, 2007), also usefulness of ultrasound was proposed in registration (Oszwald et al., 2008). When data is processed it is possible to use so called navigators,

which can be specialized trackers (Meskers, Fraterman, van der Helm, Vermeulen & Rozing, 1999) or robots (Honl et al., 2003). However, usage of robots in trauma cases was mostly studied in laboratory settings (Oszwald et al., 2010). Moreover, trauma cases are more complex and more individualized approach is needed. One definition of a fracture is that it is a severe injury to the soft tissues with loss of continuity of the bone. The definition explains why fracture treatment is so demanding and unpredictable. Common surgical approaches have to be modified in trauma setting, moreover the time between injury and treatment is often limited, therefore preparation of individualized computer assisted navigation for the cases is very hard to obtain.

4. RAPID PROTOTYPING

In recent years there is growing interest in process called rapid prototyping. Especially trauma surgeons can benefit from such modality in complex cases due to problems regarding traumathology mentioned above. The process can be simply described as creating a 3D model of the structures from source image data. In medical field the data is collected mostly by CT. It is known that based on CT scans some physical properties and detailed geometry of the bone structure can be visualised (Falchi & Rollandi, 2004). The greatest benefit of rapid prototyping is the possibility to re-create surgical steps prior to the actual surgery. This include choosing the best surgical approach, sequence of fracture elements reposition and method of definite fixation.

Such a visualisation process usually requires a few steps:

- Properly establishing the region of interest, or ROI,
- Acquisition of a series of flat slice images of the ROI, often using CT,
- Recombining the images into a three-dimensional object,
- Post-processing of the object to remove any possible artefacts,
- Preparation for 3d printing,
- Printing and optional post-processing of the physical object.

Depending on the complexity of the model and printing time, the process can take even a few days. Some cases require high resolution of CT scans to preserve crucial detail, which often results in long processing and conversion times. Very complex, three-dimensional objects that result from such a process can sometimes require introduction of additional mechanical supports into the model. Lack of such supports can cause the physical representation to be brittle and of limited use to the team. Very complex objects will sometimes require dividing into multiple parts for easier printing, assembly or visualisation of the ROI. Another problem originates in subtle model errors, which can sometimes be challenging and time-consuming to find and make printing impossible.

Choosing the proper 3D printing technology for a particular case is very important, as different methods give different results at a different cost. The most widely used methods include:

- Stereolithography, or SLA, which is a method based on laser-hardening of special type of light sensitive resin in a layered fashion. This method produces very fine detail and is relatively cheap but takes a long time.
- Digital Light Processing, or DLP, which is similar to SLA but uses arc lamps or other sources of light and a liquid crystal panel.
- Fused Deposition Modeling, or FDM, which is the most widely used method in personal 3D printers. The machine builds the object by depositing heated material, which then forms thermally fused layers. It is very cheap and can be quite fast while maintaining moderate quality. Also, various materials can be used giving the object different properties like density, hardness or colour. In more advanced printers more than one material can be used to print, resulting in more advanced and complex objects, like a bone with soft, transparent tissue covering it. One of the main drawback of this method is needing support material for floating elements or overhangs.
- Selective Laser Sintering, or SLS. This method uses a high power laser that heats parts of a layer of powdered material. After processing one layer, another one is deposited and sintered until the object is complete. This method can produce objects made of plastics or metals, is fast and accurate, but quite expensive, as it requires a large amount of powdered material.
- Selective Laser Melting, or SLM, which is similar to SLS. The difference is that the material is fully melted, resulting in a stronger bond.

The methods mentioned above can provide different results and levels of detail even for the same object. That's why it is important to optimize the model with desired precision and ROI in mind. By implementing multimaterial printing techniques it is possible to create an object that can imitate the structure of the tissue in the ROI. The synthetic tissue can be touched and felt by the surgeon. It is impossible to imitate such an experience with even the best simulation software using just rendered images.

5. CASE PRESENTATION

A male age 40 was admitted to the hospital due to multifragmentary fracture of proximal tibia due to fall while driving a quad. The fracture was diagnosed as Schatzker type V fracture-dislocation of the proximal tibia. Gross impaction of tibial plateau was recognised at initial X-rays (fig. 1).

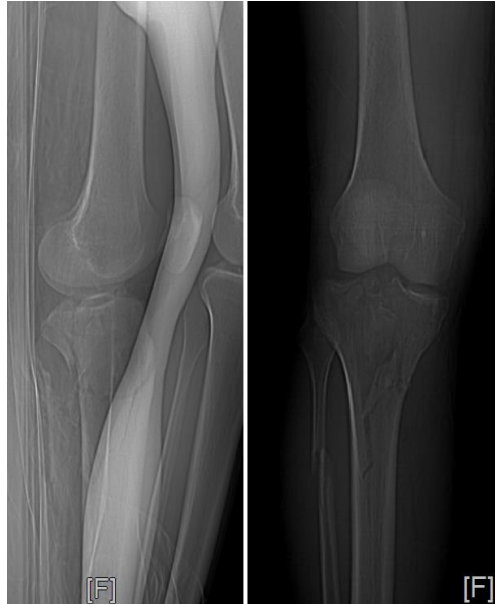

Fig. 1. Preoperative X-ray

CT of the affected joint was obtained. Due to severe swelling of the soft tissues surrounding the fracture site, the patient was immobilised in bed with traction of 8 kg. Based on the CT scans rapid prototyping model was accustomed prior to the surgery in technique described above. The object was printed using Creality CR-10S with a 0,3 mm nozzle, 40% rectilinear infill, with 0,2mm layer thickness and with support material enabled. The filament was 1,75 mm PLA. After the swelling reduction surgery was performed. Day before the planned procedure, the main surgeon was able to practice the fracture reduction of the 3D replica (fig. 2). The The object during the printing process was shown in Figure 3.

The model gave a great insight into the necessary monouvers during the surgery. Moreover, due to large posterior extension of the medial tibial condyle fracture, the medial surgical approach was modified to enable adequate exposure of the fracture site. Implants could be adequately measured and prepared in advance. In surgeons opinion the utility of the 3D replica shortened the surgery time, and facilitated better reduction of the fracture, while it was known prior to the surgery that additional supporting screws will be necessary to obtain satisfactory reduction and fixation. After surgery a continues passive motion was introduced, and walking with ground contact. The patient regained full painless range of motion and returned to off-road quad riding.

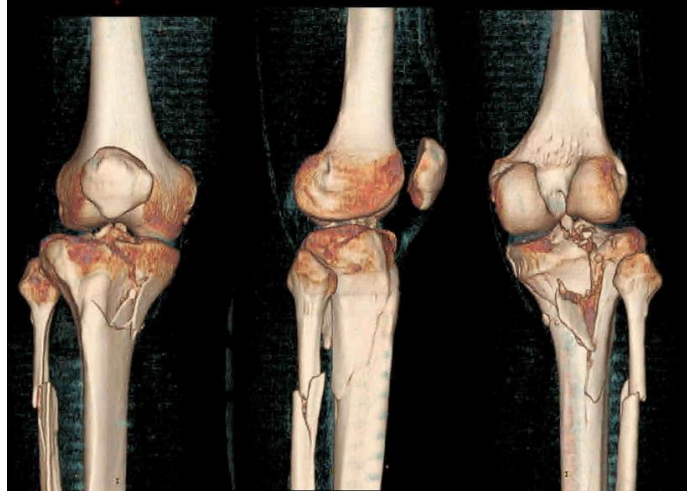


Fig. 2. 3-D reconstruction of fractured tibial plateau with visible multiple fracture lines




Fig. 3. The object during the printing process

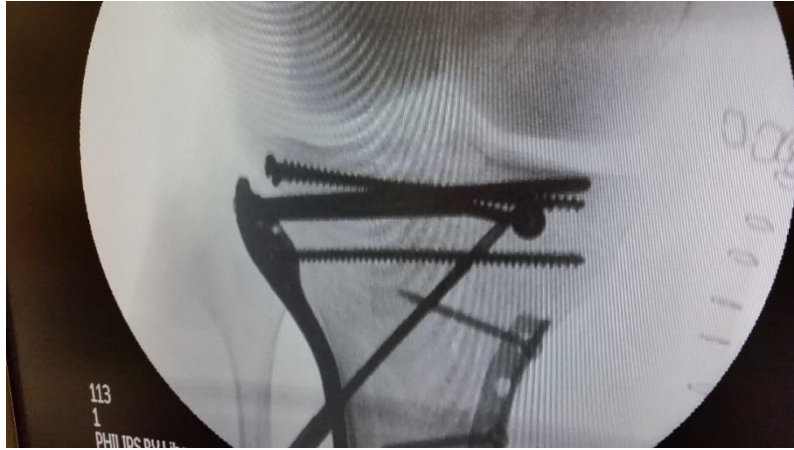

Fig. 4. Intra-operative fluoroscopic image of reconstructed tibial plateau

6. CONCLUSION

Trauma surgery is a demanding surgical speciality, due to close connection of anatomy, physiology and physics. Several modalities such as conventional radiography, MRI or CT were introduced in the past and widely used for diagnostic purposes. However, planning of trauma procedure is relatively hard and requires from the surgeon the ability to create imaginative 3-D model of the broken bone in order to re-create the bony anatomy during surgery. In simple fractures, this process is straightforward. However, complex intra-articular fractures with multiple fracture lines can be very difficult to fully understand the movements needed for restoring bony anatomy. Therefore, in complex trauma cases rapid prototyping might be useful as a assisting tool in surgery planning. The main advantage of these process is that surgeon can actually feel and see in 1/1 scale ratio the operated area, which influences surgical approach, technique and im-plants which are to be used. A pilot study wit a complex intra-articular tibial fracture showed its usefulness in planning and performing the surgery. We believe that in future more and more such applications will be used in everyday practice in orthopaedic surgery.

REFERENCES

- The ATLS Subcommittee, American College of Surgeons' Committee on Trauma, and the International ATLS working group. (2013). Advanced trauma life support (ATLS): the ninth edition. *Journal of Trauma and Acute Care Surgery*, 74(5), 1363-1366. doi:10.1097/TA.0b013e31828b82f5
- Bargar, W. L., Bauer, A., & Börner, M. (1998). Primary and revision total hip replacement using the Robodoc system. *Clinical Orthopaedics and Related Research*, 354, 82-91.

- Bégué, T. (2014). Articular fractures of the distal humerus. *Orthopaedics & Traumatology: Surgery & Research*, 100(suppl_1), S55–S63. doi:10.1016/j.otsr.2013.11.002
- Berrington de González, A., Mahesh, M., Kim, K. P., Bhargavan, M., Lewis, R., Mettler, F., & Land, C. (2009). Projected Cancer Risks From Computed Tomographic Scans Performed in the United States in 2007. *Archives of Internal Medicine*, 169(22), 2071–2077. doi:10.1001/archinternmed.2009.440
- Bächler, R., Bunke, H., & Nolte, L. P. (2001). Restricted surface matching? Numerical optimization and technical evaluation. *Computer Aided Surgery*, 6(3), 143–152. doi:10.1002/igs.1017
- Crawford, R., Walley, G., Bridgman, S., & Maffulli, N. (2007). Magnetic resonance imaging versus arthroscopy in the diagnosis of knee pathology, concentrating on meniscal lesions and ACL tears: a systematic review. *British Medical Bulletin*, 84(1), 5–23. doi:10.1093/bmb/ldm022
- Cunningham, B., Jackson, K., & Ortega, G. (2014). Intraoperative CT in the Assessment of Posterior Wall Acetabular Fracture Stability. *Orthopedics*, 37(4), e328–e331. doi:10.3928/01477447-20140401-51
- Dale, J. D., Ha, A. S., & Chew, F. S. (2013). Update on Talar Fracture Patterns: A Large Level I Trauma Center Study. *American Journal of Roentgenology*, 201(5), 1087–1092. doi:10.2214/AJR.12.9918
- Falchi, M., & Rollandi, G. A. (2004). CT of pelvic fractures. *European Journal of Radiology*, 50(1), 96–105. doi:10.1016/j.ejrad.2003.11.019
- Honl, M., Dierk, O., Gauck, C., Carrero, V., Lampe, F., Dries, S., Quante, M., Schwieger, K., Hille, E., & Morlock, M. M. (2003). Comparison of robotic-assisted and manual implantation of a primary total hip replacement. A prospective study. *The Journal of Bone and Joint Surgery. American Volume*, 85-A(8), 1470–1478.
- Jacob, A. L., Messmer, P., Kaim, A., Suhm, N., Regazzoni, P., & Baumann, B. (2000). A whole-body registration-free navigation system for image-guided surgery and interventional radiology. *Investigative Radiology*, 35(5), 279–288. doi:10.1097/00004424-200005000-00001
- Jenkins, P. J., Slade, K., Huntley, J. S., & Robinson, C. M. (2008). A comparative analysis of the accuracy, diagnostic uncertainty and cost of imaging modalities in suspected scaphoid fractures. *Injury*, 39(7), 768–774. doi:10.1016/j.injury.2008.01.003
- Kemppainen, J., Pennock, A. T., Roocroft, J. H., Bastrom, T. P., & Mubarak, S. J. (2014). The Use of a Portable CT Scanner for the Intraoperative Assessment of Talocalcaneal Coalition Resections: *Journal of Pediatric Orthopaedics*, 34(5), 559–564. doi:10.1097/BPO.0000000000000176
- Lauterbur, P. C. (1973). Image Formation by Induced Local Interactions: Examples Employing Nuclear Magnetic Resonance. *Nature*, 242(5394), 190–191. doi:10.1038/242190a0
- MacDessi, S. J., Jang, B., Harris, I. A., Wheatley, E., Bryant, C., & Chen, D. B. (2014). A comparison of alignment using patient specific guides, computer navigation and conventional instrumentation in total knee arthroplasty. *The Knee*, 21(2), 406–409. doi:10.1016/j.knee.2013.11.004
- Meskers, C. G. M., Fraterman, H., van der Helm, F. C. T., Vermeulen, H. M., & Rozing, P. M. (1999). Calibration of the “Flock of Birds” electromagnetic tracking device and its application in shoulder motion studies. *Journal of Biomechanics*, 32(6), 629–633. doi:10.1016/S0021-9290(99)00011-1
- Mulford, J. S., Babazadeh, S., & Mackay, N. (2016). Three-dimensional printing in orthopaedic surgery: review of current and future applications: Three-dimensional printing in orthopaedic surgery. *ANZ Journal of Surgery*, 86(9), 648–653. doi:10.1111/ans.13533
- Ohashi, K., Sanghvi, T., El-Khoury, G. Y., Ahn, J. M., Bennett, D. L., Geijer, M., Inaoka, T., Berbaum, K. (2015). Diagnostic accuracy of 3D color volume-rendered CT images for peroneal tendon dislocation in patients with acute calcaneal fractures. *Acta Radiologica*, 56(2), 190–195. doi:10.1177/0284185114522224
- Röntgen, W. C. (1896). On a New Kind of Rays. *Nature*, 53, 274–276. doi:10.1038/053274b0

- Oszwald, M., Citak, M., Kendoff, D., Kowal, J., Amstutz, C., Kirchoff, T., Nolte, L. P., Krettek, C., & Hüfner, T. (2008). Accuracy of navigated surgery of the pelvis after surface matching with an a-mode ultrasound probe. *Journal of Orthopaedic Research*, 26(6), 860–864. doi:10.1002/jor.20551
- Oszwald, M., Westphal, R., Bredow, J., Calafi, A., Hüfner, T., Wahl, F., Krettek, Ch., & Gosling, T. (2010). Robot-assisted fracture reduction using three-dimensional intraoperative fracture visualization: An experimental study on human cadaver femora. *Journal of Orthopaedic Research*, 28(9), 1240–1244. doi:10.1002/jor.21118
- Puig, S., Kuruvilla, Y. C. K., Ebner, L., & Endel, G. (2015). Magnetic resonance tomography of the knee joint. *Skeletal Radiology*, 44(10), 1427–1434. doi:10.1007/s00256-015-2178-5
- Rahmathulla, G., Nottmeier, E. W., Pirris, S. M., Deen, H. G., & Pichelmann, M. A. (2014). Intraoperative image-guided spinal navigation: technical pitfalls and their avoidance. *Neurosurgical Focus*, 36(3), E3. doi:10.3171/2014.1.FOCUS13516
- Rajasekaran, S., Karthik, K., Ravi Chandra, V., Rajkumar, N., & Dheenadhayalan, J. (2010). Role of intraoperative 3D C-arm-based navigation in percutaneous excision of osteoid osteoma of long bones in children: *Journal of Pediatric Orthopaedics B*, 19(2), 195–200. doi:10.1097/BPB.0b013e328333997a
- Richmond, C. (2004). Sir Godfrey Hounsfield. *BMJ*, 329, 687. doi:10.1136/bmj.329.7467.687
- Rosas, H. G. (2014). Magnetic Resonance Imaging of the Meniscus. *Magnetic Resonance Imaging Clinics of North America*, 22(4), 493–516. doi:10.1016/j.mric.2014.07.002
- Segal, L. S., & Shrader, M. W. (2013). Missed fractures in paediatric trauma patients. *Acta Orthopaedica Belgica*, 79(6), 608–615.
- Shin, A. Y., Morin, W. D., Germany, J. D., Jones, S. B., & Lapinsky, A. S. (1996). The Superiority of Magnetic Resonance Imaging in Differentiating the Cause of Hip Pain in Endurance Athletes. *The American Journal of Sports Medicine*, 24(2), 168–176. doi:10.1177/036354659602400209
- Shindle, M. K., Foo, L. F., Kelly, B. T., Khanna, A. J., Domb, B. G., Farber, A., Wanich, T., & Potter, H. G. (2006). Magnetic Resonance Imaging of Cartilage in the Athlete: Current Techniques and Spectrum of Disease. *The Journal of Bone and Joint Surgery (American)*, 88(suppl_4), 27–46. doi:10.2106/JBJS.F.00614
- Silva Jr., J. R., Hayashi, D., Yonenaga, T., Fukuda, K., Genant, H. K., Lin, C., Rahmouni, A., & Guermazi, A. (2013). MRI of bone marrow abnormalities in hematological malignancies. *Diagnostic and Interventional Radiology*, 19, 393–399. doi:10.5152/dir.2013.067
- Taylor, R. H., Joskowicz, L., Williamson, B., Guéziec, A., Kalvin, A., Kazanzides, P., Van Vorhis, R., Yao, J., Kumar, R., Bzostek, A., Sahay, A., Börner, M., & Lahmer, A. (1999). Computer-integrated revision total hip replacement surgery: concept and preliminary results. *Medical Image Analysis*, 3(3), 301–319.
- Wong, K. P. L., Han, A. X., Wong, J. L. Y., & Lee, D. Y. H. (2017). Reliability of magnetic resonance imaging in evaluating meniscal and cartilage injuries in anterior cruciate ligament-deficient knees. *Knee Surgery, Sports Traumatology, Arthroscopy*, 25(2), 411–417. doi:10.1007/s00167-016-4211-1
- Zheng, G., Kowal, J., González Ballester, M. A., Caversaccio, M., & Nolte, L.-P. (2007). Registration techniques for computer navigation. *Current Orthopaedics*, 21(3), 170–179. doi:10.1016/j.cuor.2007.03.002
- Zheng, G., & Nolte, L. P. (2015). Computer-Assisted Orthopedic Surgery: Current State and Future Perspective. *Frontiers in Surgery*, 2, 66. doi:10.3389/fsurg.2015.00066