

BIOMECHANICS OF THE UPPER LIMB

Łukasz Jaworski¹, Robert Karpiński², Angelika Dobrowolska³

¹ Faculty of Mechanical Engineering and Management, Poznan University of Technology,
3 Piotrowo St., 60-965 Poznań, Poland, email: lukasz.m.jaworski@student.put.poznan.pl

² Biomedical Engineering Department, Faculty of Mechanical Engineering, Lublin University of Technology,
36 Nadbystrzycka St., 20-618 Lublin, Poland, email: robert.karpinski@pollub.edu.pl

³ Faculty of Medicine with Dentistry Division, Medical University of Lublin,
1 Raławickie Ave., 20-059 Lublin, Poland

ABSTRACT

The article presents basics of the human upper limb's anatomy, including skeletal system, joints and basic division of muscles in the limb. The biomechanics of the upper limb is introduced. The range of performed motions is depicted. The possible applications of anatomy and biomechanics of the upper limb are shown.

KEYWORDS: upper limb, anatomy, biomechanics, biomechanism

BIOMECHANIKA KOŃCZYNY GÓRNEJ

STRESZCZENIE

Artykuł prezentuje podstawy anatomii kończyny górnej człowieka, z uwzględnieniem układu kostnego, stawów oraz wstępnego podziału mięśni działających na kończynę. Przedstawiono biomechanikę kończyny górnej. Opisano zakres ruchów realizowanych przez kończynę. Pokazano możliwe zastosowania wiedzy z dziedziny anatomii i biomechaniki.

SŁOWA KLUCZOWE: kończyna górna, anatomia, biomechanika, biomechanizm

1. Introduction

The upper limb plays a distinctive part in daily activities as well as in human interaction, such as communication and expression of emotions. Thanks to joints connecting bones, the upper limb has 30 degrees of freedom, which translates to a very wide range of motion. Its complex structure allows to perform a series of movements, not only grasping, but also of cognitive nature through touching, lifting, rotating and relocating of held objects. A complicated system of muscles and sensory receptors is responsible for the accuracy of performed moves.

2. Basic anatomy of human upper limb

The upper limb is divided into two parts: shoulder girdle, and arm. The shoulder girdle consists of the clavicle (or collarbone) and scapula (or shoulder blade). The clavicle is located above the first rib and sets a border between the neck and chest. The scapula is a wide, flat, triangular bone located in upper area of the human back, connected with torso only via muscles. Meanwhile the shoulder girdle is integrated with the axial skeleton through the sternoclavicular joint [1, 2, 3].

The arm is built of the humerus, ulna, radius bone, and also of 8 carpal bones of the wrist, 5 metacarpal bones and 14 phalanges in fingers. Altogether, the human upper limb contains 37 bones [1, 3] as it is shown in Figure 1.

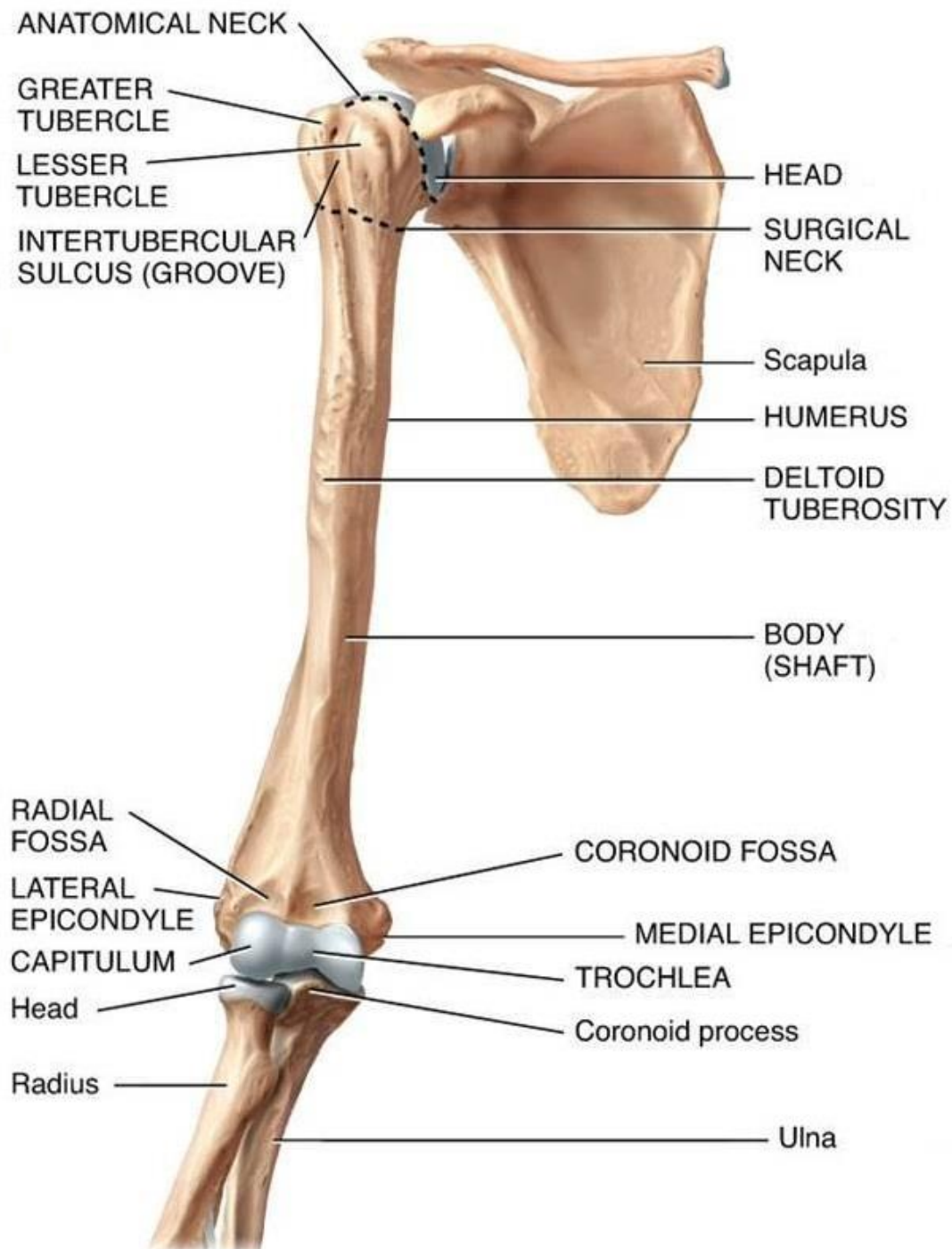


Fig. 1. Shoulder girdle and arm [13]

The humerus is the largest and the longest bone of the upper limb. It is divided into three sections: the body in the middle and two humeral extremities – upper and lower. The upper extremity creates a head for the shoulder joint, while the lower extremity acts as a head for the elbow joint [1, 3, 5].

The forearm contains two long, parallel and slightly curved bones: radius and ulna. The ulna is on the side opposite to the thumb, while the radius is located on the thumb side of the wrist. Due to the fact, that each bone plays crucial part in opposite joints, their structure is differentiated –

the proximal extremity of the ulna, connecting the forearm with the arm via elbow joint, is more massive than the lower extremity; the radial bone is connected with the wrist, hence the complexity of the lower extremity [1, 2, 3, 4].

The hand consists of 27 bones and is divided into three parts – the wrist, metacarpus and fingers. The wrist contains 8 carpal bones positioned in two rows. Next, there are 5 long, metacarpal bones, numbered from the thumb. The fingers are built of phalanges. Each finger has 3 phalanges (proximal, intermediate and distal), except for the thumb having only proximal and distal phalanx [1, 3].

All of the upper limb's movements are possible thanks to numerous joints: the shoulder joint, elbow joint, wrist, and joints of the hand.

The shoulder joint connects the arm and the shoulder girdle. Similar to a hip joint, it is a multiaxial synovial ball and socket joint [3, 6, 7]. The head of the humerus, shaped as a ball, fits the spherical surface of the glenoid cavity of the scapula, acting as a socket of the joint. Surfaces of the head and cavity are covered with an articular cartilage, which properties are thoroughly described by Karpiński et al.[7].

The wide range of motion in this joint is achieved thanks to shallow embedment of the head inside the socket and a spacious, strong articular capsule surrounding the joint. The capsule is additionally strengthened by muscles, tendons and ligaments, such as glenohumeral, coracohumeral and coracoacromial ligaments. The anatomical structure of the shoulder joint is shown in Fig. 2.

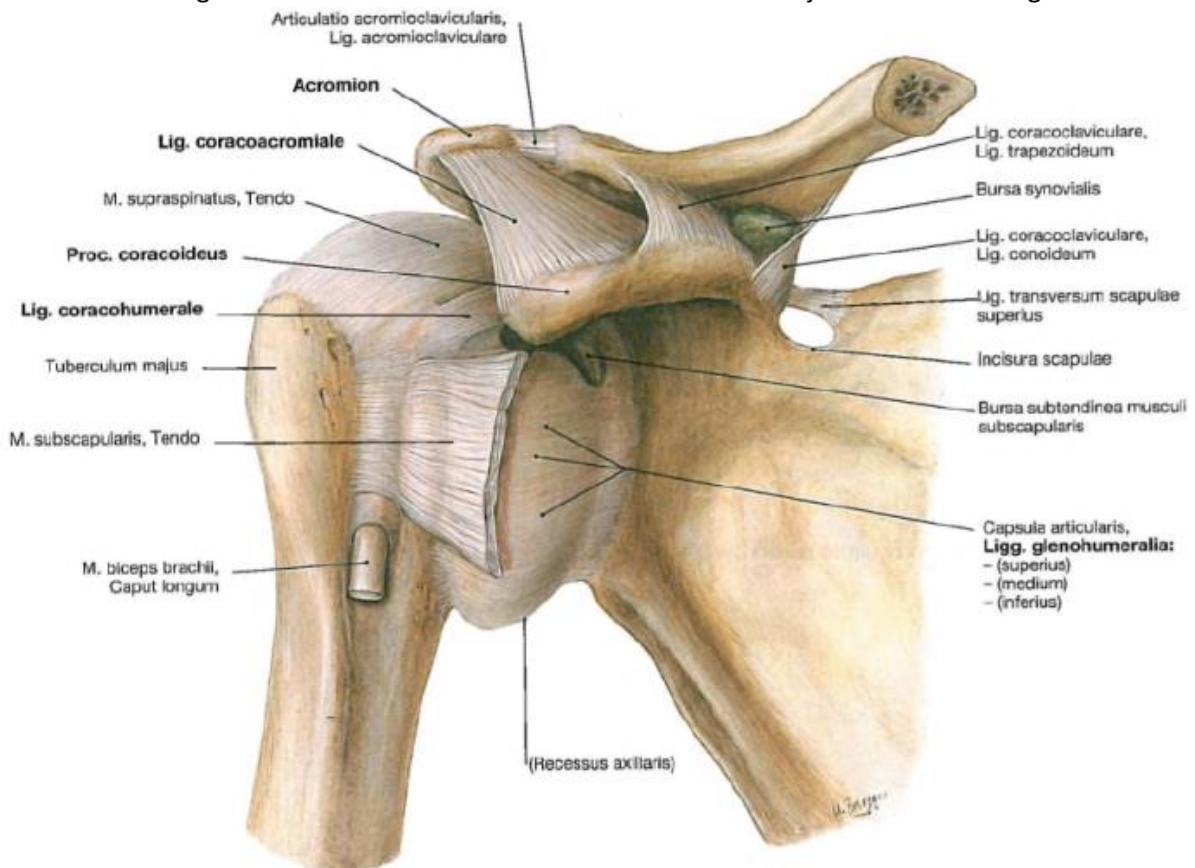


Fig. 2. Right shoulder joint (front view) [4]

The elbow is a complex joint consisting of the humeroulnar, humeroradial and proximal radioulnar joints, surrounded by a common joint capsule. Stability in a frontal plane is ensured mainly by the ulnar collateral ligament and radial collateral ligament. Such as in the shoulder joint, articular surfaces are covered with the articular cartilage. The elbow joint is shown in Fig. 3.

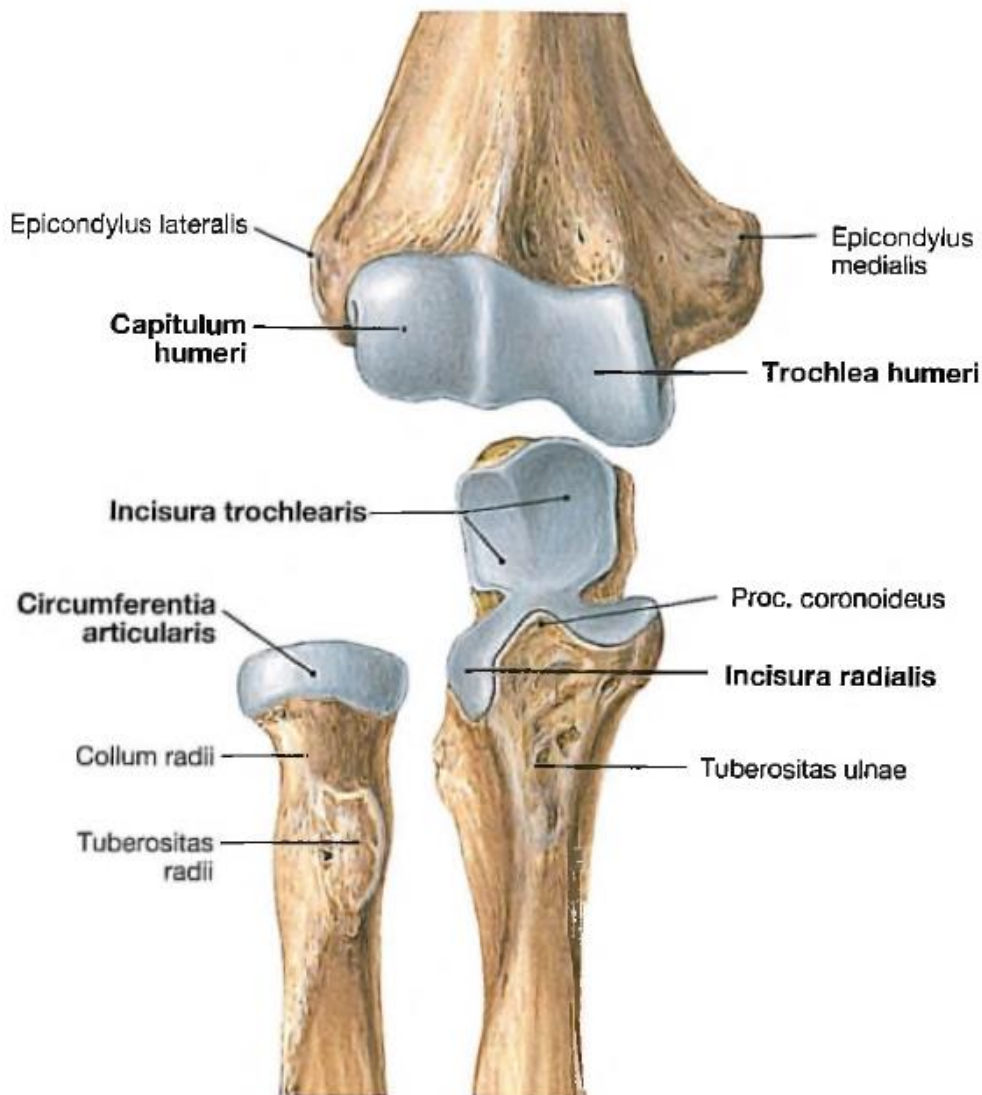


Fig. 3. Right elbow joint (front view) [4]

The hand, as the last part of the upper limb, is possibly one of the most sophisticated, due to several joints enabling movement of the hand, such as the radiocarpal (wrist) joint, intercarpal joints, metacarpophalangeal joints and interphalangeal joints in fingers [1, 3, 8].

The skeletal movement is generated by total amount of 43 muscles connected to these structures. Muscles of the upper limb are divided into four groups: muscles of the shoulder girdle, the arm, the forearm and the hand [3, 4]. An assessment of force capacity of muscles is one of the factors in diagnostics of upper limb, especially in athletics. Studies of this factor are conducted on dedicated stations using torque acting on a lever during an examination. On the basis of these results, it is possible to predict forces induced by muscles with a use of mathematical equations.

3. Biomechanics of the human upper limb

3.1. Range of motion

Thanks to the structures described above, it is possible for the upper limb to perform a series of movements in different planes (Figure 4.), which help in interaction with the surrounding world on daily basis. While studying the kinematics of upper limb's motion, we can distinguish groups of moves related to joints, in which they are executed.

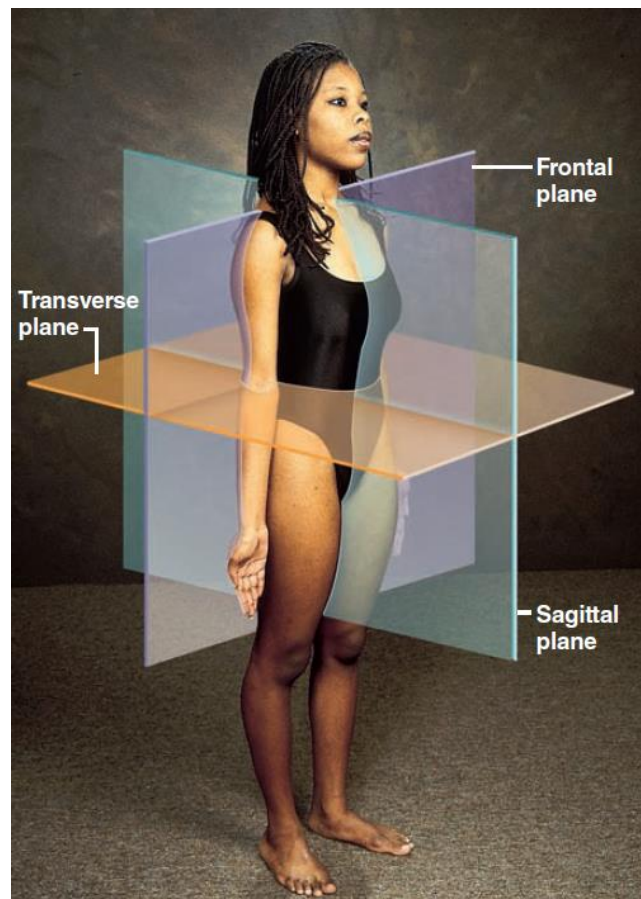


Fig. 4. Standard anatomical posture with major movements shown [12]

The shoulder joint allows to perform motions such as abduction and adduction (coronal plane), flexion and extension (sagittal plane), horizontal abduction and adduction (transverse plane), and also internal and external rotation. In the elbow joint, there are two pairs of possible moves – elbow flexion/extension and forearm supination/pronation. The wrist provides the flexion/extension and radial/ulnar deviation [8]. The range of described motions is shown in Table 1.

Table 1. The movement range of each DOF [10]

Degrees of freedom	Movement range
Shoulder flexion/extension	150°-180°/40°-50°
Shoulder abduction/adduction	180°/30°-40°
Shoulder internal/external rotation	70°-95°/40°-70°
Elbow flexion/extension	135°-140°/0°
Forearm supination/pronation	85°-90°/70°-90°
Wrist flexion/extension	73°/70°
Wrist radial deviation/ulnar deviation	27°/27°

3.2. Upper limb as a biomechanism

In terms of kinematics, the upper limb is an open kinematic chain starting in the sternoclavicular joint and ending in finger joints. Due to the specific structure of human joints, only rotational motions in these joints are possible. In case of structural analysis of the limb as the biomechanism, individual bones are considered as movable parts, and their joints as kinematic pairs of different classes (class III – 3 degrees of freedom, class IV – 2DoF, class V – 1 DoF) [8]. Representation of this approach is presented in Fig. 5.

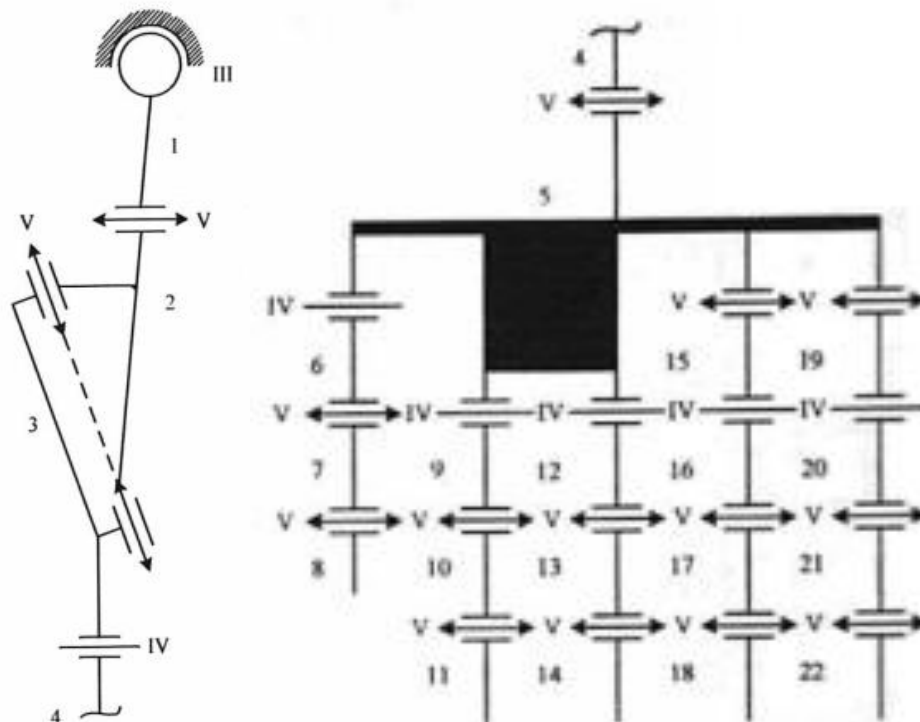


Fig. 5. Structural diagram of the upper limb excluding the shoulder girdle [8]

Information procured while analyzing anatomical and biomechanical properties of the upper limb can be used in various situations. They are used in the process of manufacturing prosthetic implants, such as the shoulder joint endoprosthesis, or in designing devices for rehabilitation purposes [10]. Musculoskeletal models, which apply basic laws of mechanics to the human musculoskeletal system, have a variety of applications, as for instance they can lead to understanding of the impact of external forces acting on the limb, which can be implemented in the field of ergonomics. They find a use in determining a correlation between structural alterations in the limb and changes in its functions [11].

4. Conclusions

The human upper limb is a complicated system of bones, joints, muscles and other elements. Its structure allows to perform the set of movements essential in daily activities. Thanks to previous studies and modern technology, it is possible to use procured knowledge in fields of science inclined toward the improvement of people's wellness, including rehabilitation or ergonomics, as well as while doing so to broaden our knowledge and understanding of the behavior of each structure within the upper limb.

5. References

- [1] A. Bochenek, M. Reicher, *Anatomia człowieka*. Warsaw, Poland: Wydawnictwo Lekarskie PZWL, 1978.
- [2] M. Reicher, *Anatomia człowieka*, vol. 1, *Anatomia ogólna, kości, stawy i więzadła, mięśnie*, 10th ed. Warsaw, Poland: Wydawnictwo Lekarskie PZWL, 1990.
- [3] E. Switoński, A. Guzik-Kopyto, *Biomechanika kończyny górnej*, *Biomechanika narządu ruchu człowieka*, D. Tejszerska et al., Ed. Gliwice, Poland: Wydawnictwa Naukowe Instytutu Technologii Eksploatacji – Państwowego Instytutu Badawczego, 2011, pp. 241–224.
- [4] W. Woźniak, K.S. Jędrzejewski, *Sobotta. Atlas anatomii człowieka*. Wrocław, Poland: Elsevier Urban & Partner, 2012.

- [5] W. Sylwanowicz, A. Michajlik, *Anatomia i fizjologia człowieka*. Warsaw, Poland: Wydawnictwo Lekarskie PZWL, 1980
- [6] R. Karpiński, Ł. Jaworski, J. Szabelski, "The design and structural analysis of the endoprosthesis of the hip joint," *Applied Computer Science*, vol. 12, no. 1, pp. 87–95, 2016.
- [7] R. Karpiński, Ł. Jaworski, J. Zubrzycki, "Structural analysis of articular cartilage of the hip joint using finite element method," *Adv. Sci. Technol. Res. J.*, vol. 10, no. 31, pp. 240–246, 2016.
- [8] M. Gzik *et al.*, *Biomechanika i inżynieria rehabilitacyjna*. Warsaw, Poland: Akademicka Oficyna Wydawnicza EXIT, 2015.
- [9] A. Freivalds, *Biomechanics of the upper limbs*. Boca Raton: CRC Press LLC, 2004.
- [10] Y. Chen *et al.*, "Design of a 6-DOF upper limb rehabilitation exoskeleton with parallel actuated joints," *Bio-Medical Materials and Engineering*, vol. 24, no. 6, pp. 2527–2535, 2014.
- [11] B. Bolsterlee *et al.*, "Clinical applications of musculoskeletal modelling for the shoulder and upper limb," *Med. Biol. Eng. Comput.*, vol. 51, no. 9, pp. 953–963, 2013.
- [12] K. S. Saladin *et al.*, *Human Anatomy*, 5th ed. New York, NY: McGraw-Hill Education, 2016.
- [13] T. Slobodzian (2013, January 24). Anatomy4 - Skeletal Upper Limb [Online]. Available: <https://www.studyblue.com/>